

## ARM SLING VERSUS FIGURE OF EIGHT FOR TREATING MIDSHAFT CLAVICLE FRACTURE IN ADULTS – A SYSTEMATIC REVIEW

**Teddy Arga Saputro**

Medical Doctor of Sultan Imanuddin Hospital, Pangkalan Bun Central Kalimantan,  
Indonesia

teddy.99.td@gmail.com

Received: 05-05-2021

Revised : 20-06-2021

Accepted: 26-06-2021

### **Abstract**

**Introduction:** The clavicle is a long, dual-curved bone that forms the only direct link between the axial and appendicular skeletons. Clavicle fracture is the most frequent trauma of the scapular girdle, and involves the midshaft. Although the proportion managed operatively has increased in recent years, the majority (80%) occur at the midshaft are treated non-operatively. Conservative treatments (including figure of eight and arm sling) has a high union rate and good clinical outcome in majority of cases, but very few randomized studies have compared the two. Therefore, a systematic review is needed to compare between arm sling and figure of eight bandage for treat the midshaft clavicle fracture in adults. The author hopes that this systematic review can be the consideration for the better treatment in closed clavicle fracture in adults. **Method:** The following strategy was used terms on several journals of comparison between arm sling with figure of eight bandage for threatening midshaft clavicle fracture in adults. Preferred Reporting Items for Systematic Reviews and Meta-Analyses (PRISMA) guidelines were used to perform the comprehensive data collection. The authors used 5 years publication date and English language to select an appropriate journal. **Result:** The result is presented by comparison between arm sling and figure of eight for the treatment outcomes. The author identified 11 relevant articles about comparison between arm sling and figure of eight to treat midshaft clavicle fracture in adults. The total number of patients was 3064 samples. The articles compare about the level of pain by VAS score, level of shortening and mean time of union. **Conclusion:** The arm sling has better advantages for non-operative treatment to midshaft clavicle fracture in adults than figure of eight bandage. It shows from the level of pain, level of shortening and mean time of union. The arm sling treatment has less level of pain, less level of shortening and less mean time of union than figure of eight bandage.

**Keywords:** clavicle fracture; figure of eight; arm sling.



## INTRODUCTION

The clavicle is a long, dual-curved bone that forms the only direct link between the axial and appendicular skeletons. Clavicle is the first bone in the body to be ossified (begins at 5 to 6 weeks' gestation) and the last bone to complete ossification (Kadam et al., 2018).

Clavicle fracture is the most frequent trauma of the scapular girdle, and involves the midshaft in 4 out of 5 cases (Ropars et al., 2017). Although the proportion managed operatively has increased in recent years, the majority (80%) occur at the midshaft are treated non-operatively (Goh et al., 2020). Most adults treated non surgically for midshaft clavicle fractures will heal completely. Unfortunately, based on recent studies have shown that midshaft fractures that has malunion, pain and deformity rates may be larger number compared to those reported with conventional method. Latest evidence demonstrates that operative treatment of midshaft clavicle fractures can result in better functional status and patient satisfaction than non surgical treatment in patients meeting certain criteria (Goh et al., 2020).

The rate of nonunion for completely displaced mid-shaft fractures has recently been reported to be 15.1% in a metaanalysis of 2144 fractures treated non-operatively (Goh et al., 2020). Conservative treatments (including figure of eight and arm sling) has a high union rate and good clinical outcome in majority of cases (Rasheed, 2018). The figure of eight bandage and the broad arm sling are most commonly used and, despite their wide use, very few randomized studies have compared the two (Ersen et al., 2015). A search strategy, updated in January 2014, did not find any new comparative studies on conservative interventions for treating clavicle fractures (Lenza et al., 2016). There are numerous conservative treatment options available, the most common being the use of a sling or 'figure of eight bandage (also known as figure-of-eight splint, or back-pack bandage), or a combination of these two methods (Kadam et al., 2018). Therefore, a systematic review is needed to compare between arm sling and figure of eight bandage for treat the midshaft clavicle fracture in adults. The author hopes that this systematic review can be the consideration for the better treatment in closed clavicle fracture in adults.

## METHODS

The following strategy was used terms on several journals of comparison between arm sling with figure of eight bandage for threatening midshaft clavicle fracture in adults. Preferred Reporting Items for Systematic Reviews and Meta-Analyses (PRISMA) guidelines were used to perform the comprehensive data collection. A bibliometric evaluation was done on all the search results. After searching with those keywords, the authors used 5 years publication date and English language to select the appropriate journal. Journals were reviewed from title and abstract and followed inclusion and exclusion criteria. The inclusion criteria were an original article, a full-text paper, retrospective design and compare of arm sling and figure of eight for threatening midshaft clavicle fracture in adults. The exclusion criteria were a case reports, review articles,, and no data analysis. Journal search strategy showed in figure 1.

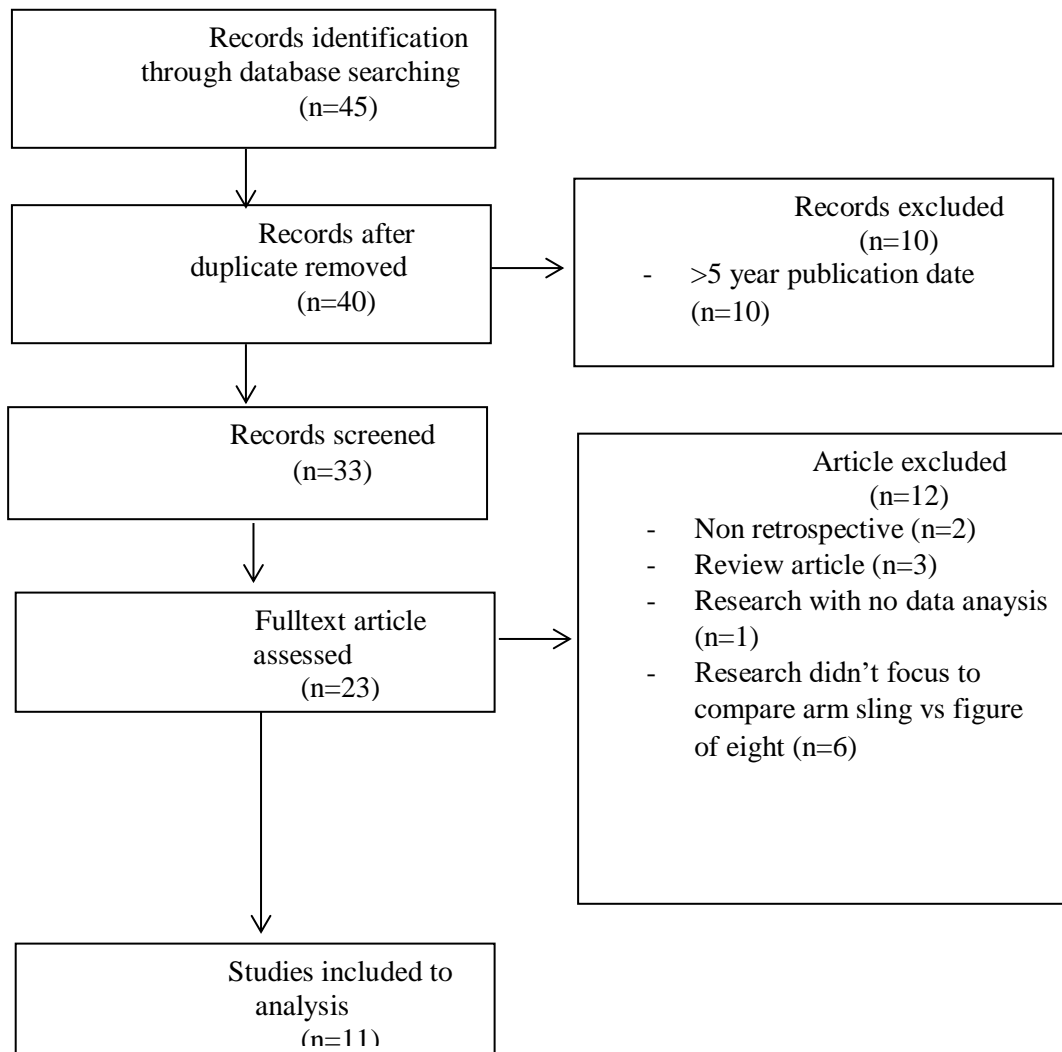


Figure 1. Flow diagram of search strategy

## RESULT AND DISCUSSION

### A. RESULT

The initial journals of 45 titles that assessed according to the inclusion and exclusion criteria, There were 11 final total number of articles which were analyzed.

Table 1. Studies included to analysis

Author	∑ Sampel	Design	Case Result
Ropars et al, 2017	79	retrospective	Sling less painfull in first 3 days
Kadam et al, 2018	100	retrospective	1.0 to 1.8 cm shortening is seen in males treated with “arm sling” as compared to 1.7-2.10 cm shortening is

			<p>seen in males treated with “figure of eight bandage”</p> <p>An average shortening of 1.0 to 1.7 cm shortening is seen in females treated with “arm sling” as compared to shortening of 1.5-2.0 cm in females treated with “figure of eight bandage</p>
Ersen et al, 2016	60	retrospective	<p>VAS less in arm sling than figure of eight bandage, but after 3 days the VAS were almost similar</p> <p>Radiological shortening: The mean shortenings in the figure of eight bandage and broad arm sling groups were 9 mm and 7.7 mm</p>
Nusrat Rasheed, Jagdesh Kumar, 2018	60	retrospective	VAS score in day 1, 7, 14 and 21 was less in sling than figure of eight
Mario Lenza et al, 2016	110	retrospective	The broad arm sling was significantly more comfortable in the first 3 days of treatment
Gyanendra et al, 2018	60	retrospective	The mean time of union was almost similar
Tagliapietra et al, 2020	122	retrospective	Fracture comminution and clavicular shortening did not influence bone healing of figure of eight bandage
Waldmann et al, 2017	2000	retrospective	Both had excellent functional outcome and very low non-union rate of 0.13%
Goh T C et al, 2016	60	retrospective	<p>Figure of eight bandage had a higher rate of non union than arm sling</p> <p>Arm sling have a higher rate of union than figure of eight</p> <p>Figure of eight had a higher score of pain than arm sling</p>

Culver et al, 2021	296	retrospective	No differences of shoulder function at 6-12 months  No differences of pain in first week  No differences of in the mean percentage of clavicle shortening
Tamaoki et al, 2017	117	retrospective	No differences of VAS score and union of both

Based on table 1, All studies used the retrospective cohort method. The total number of patients was 3064 samples with the largest number of samples in a study by (Waldmann et al., 2018) which had a total of 2000 patients of midshaft clavicle fracture.

## B. DISCUSSION

This systemic review shows us the differences output of the non-operative treatment of midshaft clavicle fracture in adults. It shows us of some differences like pain by VAS score, shortening, and mean time of union.

The study from (Ropars et al., 2017) showed that the sling treatment was less painful than the treatment with figure of eight bandage. The study of (Ersen et al., 2015) was also show us that the pain level by VAS score of figure of eight was more painful than arm sling. It was showed in first 3 days, but after that the level of pain almost similar. The study of (Rasheed, 2018) showed that the arm sling was less painful than figure of eight in day 1, 7, 14 and 21. In other hand, the study of (Tamaoki et al., 2017), 117 patients had a similar of pain level in both arm sling and figure of eight.

The shortening level was also different in arm sling treatment than figure of eight. The study of (Kadam et al., 2018) showed that 1.0 to 1.8 cm shortening was seen in males treated with “arm sling” as compared to 1.7-2.10 cm shortening is seen in males treated with “figure of eight bandage”. An average shortening of 1.0 to 1.7 cm shortening was seen in females treated with “arm sling” as compared to shortening of 1.5-2.0 cm in females treated with “figure of eight bandage. It was aslo similar with the study of (Ersen et al., 2015) about the Radiological shortening. The mean shortenings in the figure of eight bandage and broad arm sling groups were 9 mm and 7.7 mm.

About the union time, The mean time of union was almost similar based of the study of (Jha et al., 2018) and (Tamaoki et al., 2017). Unlike with the study of (Goh et al., 2020) that showed of 60 patients that arm sling have a higher rate of union than figure of eight.

This study does have a number of limitations. First, all of this research uses 5 years of publication thus allowing previous research cannot be analyzed. Secondly, some of the studies presented didn’t show the the patient conditions everyday, so it could be the bias. For these reasons, it still difficult to definitely compare between arm sling with the figure of eight bandage.

## CONCLUSION

The arm sling has better advantages for non-operative treatment to midshaft clavicle fracture in adults than figure of eight bandage. It shows from the level of pain, level of shortening and mean time of union. The arm sling treatment has less level of pain, less level of shortening and less mean time of union than figure of eight bandage.

## REFERENCE

- Ersen, A., Atalar, A. C., Birisik, F., Saglam, Y., & Demirhan, M. (2015). [Comparison of simple arm sling and figure of eight clavicular bandage for midshaft clavicular fractures: a randomised controlled study](#). *The Bone & Joint Journal*, 97(11), 1562–1565.
- Goh, T. C., Bajuri, M. Y., Nadarajah, S. C., Rashid, A. H. A., Baharuddin, S., & Zamri, K. S. (2020). [Clinical and bacteriological profile of diabetic foot infections in a tertiary care](#). *Journal of Foot and Ankle Research*, 13(1), 1–8.
- Jha, G. K., Timsina, P., Yadav, D., Lamichhane, S., & Jha, S. (2018). [Conservative Vs Operative Management of Displaced Midshaft Clavicle Fracture-A Comparative Study](#). *Biomedical Journal of Scientific & Technical Research*, 11(1), 8293–8303.
- Kadam, R., Ghodke, A., Gupta, A., Chhallani, A., Agrawal, A., & Sawant, R. (2018). [Evaluation of Clavicle Shortening in Clavicle Fractures Treated with “ARM Sling” Or “figure of Eight Bandage.”](#) *Journal of Trauma*, 13(1), 27–30.
- Lenza, M., Taniguchi, L. F. P., & Ferretti, M. (2016). [Figure-of-eight bandage versus arm sling for treating middle-third clavicle fractures in adults: study protocol for a randomised controlled trial](#). *Trials*, 17(1), 1–8.
- Rasheed. (2018). [Midshaft Clavicle Fracture; Comparison Of Poly Arm Sling And Figure Of Eight Bandage](#). *Professional Medical Journal*, 25(1).
- Ropars, M., Thomazeau, H., & Hutten, D. (2017). [Clavicle fractures](#). *Orthopaedics & Traumatology: Surgery & Research*, 103(1), S53–S59.
- Tamaoki, M. J. S., Matsunaga, F. T., da Costa, A. R. F., Netto, N. A., Matsumoto, M. H., & Belloti, J. C. (2017). [Treatment of displaced midshaft clavicle fractures: figure-of-eight harness versus anterior plate osteosynthesis: a randomized controlled trial](#). *JBJS*, 99(14), 1159–1165.
- Waldmann, S., Benninger, E., & Meier, C. (2018). [Nonoperative treatment of midshaft clavicle fractures in adults](#). *The Open Orthopaedics Journal*, 12, 1.



© 2021 by the authors. Submitted for possible open access publication under the terms and conditions of the Creative Commons Attribution (CC BY ND) license (<https://creativecommons.org/licenses/by/3.0/>).